

The spectrum of indomethacin-responsive headaches in children and adolescents

Cephalalgia

2022, Vol. 42(8) 793–797

© International Headache Society 2022




Article reuse guidelines:

sagepub.com/journals-permissions

DOI: 10.1177/03331024221076483

journals.sagepub.com/home/cep

Kenneth A Myers^{1,2,3} , Rebecca Barmherzig⁴, Nichelle R Raj⁴, Saoussen Berrahmoune¹, Pablo Ingelmo⁵, Christine Saint-Martin⁶, Afsheen Q Khan¹, Megan Kouri⁷, Cynthia Morris^{8,9}, Andrew D Hershey¹⁰, Joanne Kacperski¹⁰, Marielle A Kabbouche¹⁰, Nada Mohamed⁵, Rashmi R Rao¹¹, Ana Marissa Lagman-Bartolome¹², Amy A Gelfand⁸, Christina L Szperka⁴  and Serena L Orr¹³

Abstract

Background: Headaches with marked, specific response to indomethacin occur in children, but the phenotypic spectrum of this phenomenon has not been well-studied.

Methods: We reviewed pediatric patients with headache showing $\geq 80\%$ improvement with indomethacin, from seven academic medical centers.

Results: We included 32 pediatric patients (16 females). Mean headache onset age was 10.9 y (range 2–16 y). Headache syndromes included hemicrania continua (n = 13), paroxysmal hemicrania (n = 10), primary stabbing headache (n = 2), short-lasting unilateral neuralgiform headache attacks with conjunctival injection and tearing (n = 1), primary exercise headache (n = 1) and primary cough headache (n = 1). Adverse events were reported in 13, most commonly gastrointestinal symptoms, which often improved with co-administration of gastro-protective agents.

Conclusion: Indomethacin-responsive headaches occur in children and adolescents, and include headache syndromes, such as primary cough headache, previously thought to present only in adulthood. The incidence of adverse events is high, and patients must be co-treated with a gastroprotective agent.

Keywords

Indomethacin, paroxysmal hemicrania, hemicrania continua, primary cough headache

Date received: 12 October 2021; revised: 2 January 2022; accepted: 3 January 2022

¹Research Institute of the McGill University Health Centre, Montreal, Quebec, Canada

²Division of Child Neurology, Department of Pediatrics, Montreal Children's Hospital, McGill University, Montreal, Quebec, Canada

³Department of Neurology and Neurosurgery, Montreal Children's Hospital, McGill University, Montreal, Quebec, Canada

⁴Department of Neurology, Children's Hospital of Philadelphia and University of Pennsylvania, Philadelphia, PA, USA

⁵Department of Pediatric Anesthesiology, McGill University Health Center, Montreal, Quebec, Canada

⁶Department of Radiology, McGill University Health Center, Montreal, Quebec, Canada

⁷Faculty of Medicine, McGill University, Montreal, Quebec, Canada

⁸Child and Adolescent Headache Program, University of California San Francisco, San Francisco, CA, USA

⁹Department of Child Neurology, Cardinal Glennon Children's Hospital, St. Louis University School of Medicine, St. Louis, MO, USA

¹⁰Departments of Pediatrics and Neurology, Cincinnati Children's Hospital Medical Center and University of Cincinnati College of Medicine, Cincinnati, OH, USA

¹¹Department of Neurology, Louisiana State University Health Sciences Center and Children's Hospital New Orleans, New Orleans, LA, USA

¹²Division of Neurology, Hospital for Sick Children and Women's College Hospital, University of Toronto, Toronto, Ontario, Canada

¹³Division of Neurology, Department of Pediatrics, Alberta Children's Hospital, Cumming School of Medicine, University of Calgary, Calgary, Alberta, Canada

Corresponding author:

Kenneth Myers, Montreal Children's Hospital, MUHC Glen Site, 1001 Décarie Blvd, Montreal, Quebec, H4A 3J1, Canada.

Email: kenneth.myers@mcgill.ca

Introduction

Headaches are common in children and adolescents, with 58% estimated prevalence (1). Primary headaches, including migraine, are the most important cause of neurological disability in older children and adolescents (2). There is a subset of primary headache disorders in which headaches are often refractory to standard therapeutic interventions, but dramatic improvement is seen, usually almost immediately, with indomethacin introduction. Often termed "indomethacin-responsive headaches," the classic disorders in this group include paroxysmal hemicrania, hemicrania continua, primary cough headache, primary exercise headache, primary headache associated with sexual activity, primary stabbing headache and hypnic headache (3). These headache disorders are sufficiently rare that the precise epidemiology is unknown; the overwhelming majority of patients have adult onset, with only a few reported pediatric cases (3–7).

This observational case series aimed to describe the phenotypic spectrum of headaches in children and adolescents for which dramatic clinical improvement was seen with introduction of indomethacin.

Methods

We reviewed the clinical or research databases from six pediatric tertiary medical centers, and reviewed all patients who had received trials of indomethacin. We then collected clinical data for all patients meeting the following criteria: 1) Age <18 years at headache onset; 2) Headache showed clear improvement with indomethacin: $\geq 80\%$ reduction in headache days/month for episodic headache (typically assessed via headache diary), or $\geq 80\%$ reduction in headache severity for continuous headache (patient's perception of change in degree of pain). In each database, data were primarily collected via clinical interview and headache diary. The 80% threshold was chosen as we were interested in patients who had a dramatic response to indomethacin, but recognized that some headache patients will not have complete resolution of symptoms. The databases are independent and had been maintained for different periods of time, ranging from 1 to 23 years. Data were then entered by investigators at each site into a standardized online collection form in Research Electronic Data Capture (REDCap), designed specifically for this study. The study was approved by McGill University Health Centre Research Ethics Board.

Results

The clinical or research databases from our centers included approximately 30,000 patients,

497 of whom had indomethacin trials with reliable follow-up data.

Demographics. Thirty-two patients (16 females) meeting inclusion criteria were identified. Mean headache onset age was 10.7 y (range 2–16 y).

Headache Syndromes. 28/32 (88%) patients had a headache disorder meeting International Classification of Headache Disorders 3rd edition criteria (Table 1) (8); 13 had hemicrania continua, 10 paroxysmal hemicrania, two primary stabbing headache, one short-lasting unilateral neuralgiform headache attacks with conjunctival injection and tearing (SUNCT), one primary cough headache, and one primary exercise headache.

Headache Features. Headache was unilateral, with or without side-switching, in 24/32; of patients with unilateral pain, the headache was side-locked (i.e. occurred only on one side) in 18/24. Pain location could involve almost any region; the most commonly reported were temporal (19/32), frontal (14/32) and retro-orbital (11/32). Pain character could be variable, with 19 reporting pounding/throbbing, 15 sharp/stabbing, six pressure, and two unable to describe. Pain was severe in 19, moderate in 12, and mild in one. Pain was constant in seven; for the remainder headache duration ranged from two seconds to multiple days.

Associated Symptoms. Autonomic symptoms were reported in 17/32 patients. With respect to migrainous symptoms, 23/32 had photophobia or phonophobia, and 12/32 reported nausea/vomiting. Other reported symptoms included tinnitus, agitation, paresthesias, and vision blurring (Table 1, Supplementary Material).

Indomethacin Dosing. Age at indomethacin initiation ranged from 3 to 17 y. For patients >45 kg, mean starting dose was 56.0 mg/day (median and mode 75 mg/day; range 12.5–75 mg/day) and mean final dose 122.3 mg/day (median 125 mg/day; mode 150 mg/day; range 25–300 mg/day). For patients <45 kg, mean starting dose was 1.1 mg/kg/day (median 1.1 mg/kg/day; range 0.2–1.8 mg/kg/day) and mean final dose 2.5 mg/kg/day (median 2.1 mg/kg/day; range 1.1–5.4 mg/kg/day).

Response to indomethacin was complete (i.e. 100% resolution of pain) in 24/32; of the remaining eight patients, two reported 95% improvement, two 90%, one 85% and three 80%. A wean of indomethacin was attempted in 26/32 patients, with headaches recurring in 18 of those 26. At last review, 9/32 patients were still taking indomethacin.

Adverse events were reported in 13/32 patients (41%), including upset stomach, nausea/vomiting, bloody stools, gastroesophageal reflux, abdominal cramps, diarrhea, fatigue, dizziness, mouth ulcers, chest pains, idiopathic thrombocytopenic purpura, and easy bruising. Gastrointestinal symptoms were

Table 1. Headache Syndromes.

Syndrome	Number of Patients (males/females)	Mean Age of Onset (range)	Associated Symptoms (Number patients reporting/total)
Hemicrania continua	13 (3/10)	11.3 y (5 y to 16 y)	Photophobia (12/13), phonophobia (11/13), nausea/vomiting (7/13), conjunctival injection/lacrimation (6/13), agitation (4/13), nasal congestion/rhinorrhea (3/13), hemiparesis (3/13)*, miosis/ptosis (2/13), pulsatile tinnitus (2/13), eyelid edema (1/13), flushing (1/13)
Paroxysmal hemicrania	10 (6/4)	11.5 y (2 y to 15 y)	Photophobia (6/10), conjunctival injection/lacrimation (5/10), miosis/ptosis (4/10), nausea/vomiting (4/10), phonophobia (3/10), nasal congestion/rhinorrhea (3/10), eyelid edema (3/10), agitation (2/10), pulsatile tinnitus (1/10), unilateral vision blurring (1/10), unilateral arm paresthesia (1/10)
Primary stabbing headache	2 (1/1)	10.5 y (10 y to 11 y)	Phonophobia (2/2), conjunctival injection/lacrimation (1/2), photophobia (1/2), nausea/vomiting (1/2), pulsatile tinnitus (1/2)
SUNCT	1 (1/0)	9 y (N/A)	Conjunctival injection/lacrimation (1/1), agitation (1/1), photophobia (1/1), phonophobia (1/1), nausea/vomiting (1/1), transient hemifacial palsy (1/1)
Primary cough headache	1 (0/1)	11 y (N/A)	Agitation (1/1)
Primary exercise headache	1 (1/0)	15 y (N/A)	Photophobia (1/1), nausea/vomiting (1/1)
Unclassified	4 (4/0)	7.8 y (3 y to 13 y)	Agitation (3/4), conjunctival injection/lacrimation (2/4), photophobia (2/4), phonophobia (1/4), nasal congestion/rhinorrhea (1/4), nausea/vomiting (1/4)

* One of the patients with unilateral weakness had conversion disorder.

often ameliorated or eliminated with gastroprotective agents including omeprazole, ranitidine, and calcium carbonate. Four patients discontinued indomethacin due to adverse events, and one patient was hospitalized with gastrointestinal hemorrhage; all of these patients had headache recurrence after indomethacin was stopped.

Other Therapies. Patients had tried as many as 11 other medications or treatments other than indomethacin without success. In some cases, patients had severe complications with these other agents, including one patient who attempted suicide after starting topiramate.

Family History. A family history of headache was obtained in 23/32 patients; however, only one of these involved an indomethacin-responsive disorder. A boy with hemicrania continua starting at six years of age had a father who reported having past headaches that responded dramatically to indomethacin, as well as a mother and paternal grandmother with migraine. For the remainder of individuals with positive family history, other family members had either migraine or unclassified headaches.

Neurologic Examination, Neuroimaging. Neurologic examination was normal in 27/32 patients.

Neuroimaging was also normal or showed non-specific findings in the vast majority. Several patients had unexpected findings on neurological examination, usually of uncertain relevance to the headache presentation. One adolescent female with hemicrania continua had hemibody weakness contralateral to the side of headache pain, attributed to conversion disorder; MRI showed compression of the cisternal segment of the left cranial nerve V and an asymmetric left artery originating from the basilar artery (Figure 1). After reporting an 80% reduction in headache pain, she discontinued indomethacin due to side effects, but subsequently became pain-free with a left gasserian ganglion injection and follow-up ablation. The boy with SUNCT had headache onset following an episode of Bell's palsy; he had dysarthria and worsening of facial droop with his headaches, and MRI showed initial enhancement of cranial nerve VII which later resolved. An adolescent female with hemicrania continua had mild unilateral arm and leg weakness. An adolescent male with hemicrania continua had transiently decreased unilateral sensation in the V2/V3 distribution, postural tremor, and unilateral slowing of finger tapping. Two females with hemicrania continua had

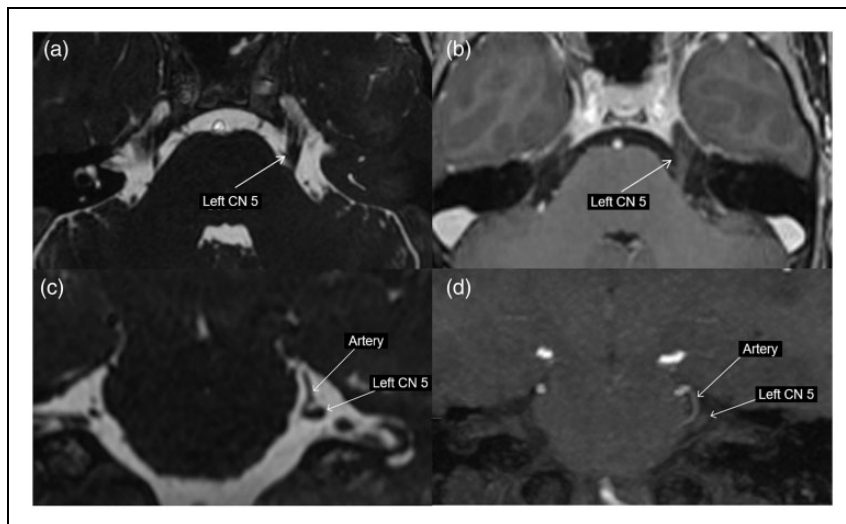


Figure 1. Brain MRI for adolescent female with hemicrania continua and suspected vascular compression: Axial heavy T2-weighted thin cuts (FIESTA) (A) and post-contrast T1-weighted (B) MRI shows asymmetric increased thickness but no enhancement of the cisternal segment of the left cranial nerve 5. (C) Coronal FIESTA and (D) coronal Maximum Intensity Projection reformation of the time of flight MR angiogram show close contact between the enlarged left cranial nerve 5 and a loop of the ipsilateral anterior inferior cerebellar artery.

diplopia or vision blurring with convergence. Two patients had uncomplicated Chiari I malformations. One patient had a 3-mm enhancing cyst in the ventral anterior portion of the pituitary gland.

Discussion

This is by far the largest cohort of pediatric indomethacin-responsive headache patients described, with prior series including only 2–8 patients (4–7). Our data illustrate several important findings regarding these rare disorders with important implications for the management of pediatric headache.

Classical indomethacin-responsive headaches occur in children and adolescents, often starting prior to puberty. Our cohort included patients with hemicrania continua, paroxysmal hemicrania, SUNCT, primary stabbing headache, primary exercise headache, and primary cough headache. Some of these disorders, such as primary cough headache, had been previously thought to occur exclusively in adults (9). Physicians must consider these entities in their differential diagnosis for pediatric headache, particularly given the treatment implications. For patients with trigeminal autonomic cephalalgia features, brain MRI with angiography is indicated to rule out vascular compression or other structural lesions (10).

Many patients had migrainous features to their headaches, which might discourage clinicians from considering a trial of indomethacin, particularly since migraines may have associated autonomic features and are often shorter duration in children. While migraine

might respond to indomethacin in any case, an index of suspicion for an indomethacin-responsive headache should be raised if patients have atypical features such as associated autonomic features, agitation, or tinnitus.

While indomethacin can elicit dramatic clinical improvement, the rate of adverse events is high, primarily related to the gastrointestinal system. Our data suggested that children did well if started on a low dose (i.e. 25 mg daily or ~ 1 mg/kg/day, whichever is less) and then were increased gradually (i.e. by 25 mg/day or 1 mg/kg/day, whichever is less) every three days until pain resolved or the patient developed intolerable side effects. Three times a day dosing is preferred to reduce side effects and increase efficacy. The optimal target dose is still not entirely clear, but if side effects are tolerable, patients may titrate up to 3–4 mg/kg/day (maximum 225 mg/day) before a decision about efficacy is made (11). In our series, children tended to tolerate the medication better if they were also prescribed a gastroprotective agent to be taken concurrently.

Although the majority of patients had an established headache disorder, many had atypical or unusual associated symptoms. Our data suggested consideration of an indomethacin trial is reasonable in children or adolescents with any of the following:

1. Clinical presentation of a known indomethacin-responsive headache disorder.
2. Side-locked unilateral headache that has not improved with other interventions.

3. Primary headache disorder that is refractory to multiple interventions, with significant reduction in quality of life or function.

As this was a retrospective case series drawn from tertiary academic centers, there is a risk of selection

bias. The true spectrum of pediatric indomethacin-responsive headaches may be broader and may include milder presentations. Prospective studies are necessary to further clarify the phenotypic spectrum and determine the optimal treatment protocol.

Clinical Implications

- Indomethacin-responsive headaches may be under-recognized in children and adolescents.
- Headache syndromes such as primary cough headache, previously only reported in adults, may occur in children.
- Although indomethacin may provide dramatic pain relief, there is a high risk for side effects and all patients should be prescribed gastroprotective agents to be taken concurrently.

Declaration of conflicting interests



The authors declared the following potential conflicts of interest with respect to the research, authorship, and/or publication of this article: SLO has research support from the Alberta Children's Hospital Research Institute and the Canadian Institutes of Health Research, receives book royalties from Cambridge University Press, and is an Associate Editor of *Headache: The Journal of Head and Face Pain*. AMLB has participated in advisory boards for Novartis, TEVA, Eli Lilly, Lundbeck and Allergan (honoraria fees were submitted to Department of Medicine, Women's College Hospital).

The other authors have indicated they have no relevant competing interests to disclose.

Funding

The authors disclosed receipt of the following financial support for the research, authorship, and/or publication of this article: KAM receives funding support from the Research Institute of the McGill University Health Centre and Fonds de Recherches du Québec – Santé.

ORCID iDs

Kenneth A Myers  <https://orcid.org/0000-0001-7831-4593>
Christina L Szperka  <https://orcid.org/0000-0003-4786-8889>

Supplemental material

Supplemental material for this article is available online.

References

1. Abu-Arafeh I, Razak S, Sivaraman B, et al. Prevalence of headache and migraine in children and adolescents: a systematic review of population-based studies. *Dev Med Child Neurol* 2010; 52: 1088–1097.
2. Group GBDNDC. Global, regional, and national burden of neurological disorders during 1990–2015: a systematic analysis for the Global Burden of Disease Study 2015. *Lancet Neurol* 2017; 16: 877–897.
3. VanderPluym J. Indomethacin-responsive headaches. *Curr Neurol Neurosci Rep* 2015; 15: 516.
4. Myers KA and Smyth KA. Preadolescent indomethacin-responsive headaches without autonomic symptoms. *Headache* 2013; 53: 977–980.
5. Tarantino S, Vollono C, Capuano A, et al. Chronic paroxysmal hemicrania in paediatric age: report of two cases. *J Headache Pain* 2011; 12: 263–267.
6. Moorjani BI and Rothner AD. Indomethacin-responsive headaches in children and adolescents. *Semin Pediatr Neurol* 2001; 8: 40–45.
7. Blankenburg M, Hechler T, Dubbel G, et al. Paroxysmal hemicrania in children—symptoms, diagnostic criteria, therapy and outcome. *Cephalalgia* 2009; 29: 873–882.
8. Headache Classification Committee of the International Headache Society (IHS) The International Classification of Headache Disorders, 3rd edition. *Cephalalgia* 2018; 38: 1–211.
9. Boes CJ, Matharu MS and Goadsby PJ. Benign cough headache. *Cephalalgia* 2002; 22: 772–779.
10. Favier I, van Vliet JA, Roon KI, et al. Trigeminal autonomic cephalgias due to structural lesions: a review of 31 cases. *Arch Neurol* 2007; 64: 25–31.
11. Marmura MJ, Silberstein SD and Gupta M. Hemicrania continua: who responds to indomethacin? *Cephalalgia* 2009; 29: 300–307.